

Digital Photography to Assess Smile Types in Class I Normal Occlusion

Issam Merzah Abdullah

University of Babylon/ college of dentistry

asd.issam@gmail.com

Abstract

The purposes of this study were to analysis smile type, evaluate, and quantify upper lip soft tissue changes in the vertical dimensions at both rest and maximum smile using digital camera. Methods thirty-eight subjects aged 18 to 24 (mean, 21.5 years) were recruited for this study. For each subject, eight measurements of upper lip position and maxillary incisor crown height at rest and in maximum smile were recorded by using digital camera. Results: low smile was more prominent and more in female than male, the high smile line come with more central incisal display and 23% upper lip contraction during smiling. Conclusions: Low smile was prominent among female and male and the variation in smile types partially may be related to the maxillary central incisor display and total lip elevation.

Keyword: dental photography, smile types, smile assessment.

الخلاصة

الغرض من هذه الدراسة لتحليل أنواع الابتسامات بالاعتماد على التغيرات التي تحدث للشفة العليا خلال الاستراحة والابتسامة باستخدام التصوير الفوتوغرافي والكاميرا الرقمية. شملت الدراسة ثمانية وثلاثين متطوع (تتراوح أعمارهم بين 18 سنة و 24 سنة). باستخدام الكاميرا ومسطره سجل لكل شخص 8 قياسات للشفة العليا خلال الاستراحة وخلال الابتسامة وأيضاً شملت قياس طول القاطع المركزي العلوي. ظهرت النتائج بان الابتسامه المنخفضة كانت هي السائدة وكانت أكثر عند النساء من الرجال وكانت الابتسامة العالية تأتي مع بروز أكثر للقاطع العلوي مع انقباض بعضله الشفة العليا بنسبه 23% خلال الابتسامة. لذلك تكون الابتسامة المنخفضة هي السائدة وذلك يرجع ربما جزءا لبروز القاطع العلوي ونسبه ارتفاع الشفة خلال الابتسامة.

الكلمات المفتاحية: التصوير الفمي، انواع الابتسامة، تحليل الابتسامة

Introduction

Improve dental esthetics is the primary objective of seeking orthodontic treatment also ideal occlusion should certainly remain the primary functional goal of orthodontics treatment, the esthetic outcome is also critical for patient satisfaction and therefore essential to the overall treatment objectives (Janzen, 1977). The importance of an attractive smile is unquestionable. A pleasing smile involves a harmonious relationship among the teeth, the lip framework, and the gingival scaffold (Adams, 1977; Sneddon, 1980; Andries *et al.*, 1997; Stevenage and McKay, 1999)

The smile may be two types either posed or spontaneous. The differences between the two are important because the posed smile is voluntary, not elicited by an emotion, static, unstrained, and reproducible. The unposed (spontaneous) smile is involuntary, induced by joy or mirth, and is not sustained (it is dynamic). It is often characterized by more lip elevation than the posed smile. When a subject is forced to mimic an unposed smile, this cannot be sustained and will appear strained and unnatural (Ackerman *et al.*, 1988).

Smile analysis and smile design have become key elements of orthodontic diagnosis and treatment planning over the last decade, recent advances in technology now permit the clinician to measure dynamic lip-tooth relationships and incorporate that information into the orthodontic problem list and biomechanical plan. Digital videography is particularly useful in both smile analysis and in doctor/patient communication. Smile design is a multifactorial process, with clinical success determined by an understanding of the patient's soft-tissue treatment limitations and the extent to which orthodontics or multidisciplinary treatment can satisfy the patient and orthodontist's esthetic goals (Peck *et al.*, 1992; Mackley, 1993; Morley and Eubank, 2001).

The purposes of this study were to analysis smile type, evaluate, and quantify upper lip soft tissue changes in the vertical dimensions at both rest and maximum smile in a groupof sample with class I normal occlusion using digital camera.

Material and Methods

The sample has been selected randomly from the students of Babylon University college of (medicine,dentistry and nursing). Out of 60persons, only 38 subjects were selected (18-24 years old). The sample was taken in terms ofthe following criteria:-

1. The sample was all of Iraqi Arab in origin.
2. No participants had undergone any maxillofacial surgery or anterior maxillarytooth prosthodontics rehabilitation.
3. No previous orthodontic treatment.
4. No extracted teeth up to the first molar.

The normal occlusion has been determined by the following criteria (Amasha, 2002; Uysal & Memili, 2005; Vitral *et al.*, 2011; Scavone *et al.*, 2008; Obaidi &Manar, 2007):

- a) Normal buccal segment relationship (class I molar relationship and class I caninerelationship).
- b) Class I incisal relationship
- c) Normal overjet and overbite (2-4mm)
- d) Minor spacing or crowding.
- e) No crossbite (anteriorly and posteriorly).

To reach the maximum social smile position, each subject was requested topresent his or her full smile a few times, and take multipicture with DSLR camera (Nikon d7100, DX-format CMOS sensor with 24.1 effective megapixels) and use ruler hold by the subject.In addition, the age and sex of each subject were recorded. All themeasurements (*Only maxillary central incisor height measured directly from the subjects*) recorded by aiding of computer and photo viewer program builded in computerand use the ruler appeared in each photo, and the methods used to obtain thesevariables are as follows.

1. Performed at both rest and maximum smiling:

- a) External upper lip length, the vertical measurement from the alar base of the nose (subnasale) to the inferior border of the upper lip (stomion superioris).
- b) Vermilion height, the vertical measurement from the superior border of thevermilion at the Cupid's bow to the inferior border of the upper lip.
- c) Maxillary central incisor display, the vertical measurement from the inferior borderof the upper lip to the incisal edge of the left central incisor.

2. Performed once in maximum smiling when applicable:

- a) Gingival display in maximum smiling, recorded in patients whose gingival displaywas noticed in the maximum smile.

Two consecutive trials were made in each subject before recording themeasurement to verify the validity of the position. Measurement of hard-tissuelandmarks by estimation over soft-tissue landmarks is a common and acceptableconcept used in various measurements in medicine (e.g., the identification of nasionand porion with a facebow).

- b) Maxillary central incisor height, the vertical measurement of the clinical crownheight of the maxillary left central incisor (figure 1&2).

The measurement was made by photo viewer software build in computer. Smile pattern was classified according to the 3 categories defined by Tjan et al, (1984) relating to the anterior maxillary tooth crown exposure at maximum smile: “low smile” displaying less than 75% of the clinical crown height of the maxillary anterior teeth, “average smile” revealing 75% to 100% of the maxillary anterior crown height, and “high smile” exposing the whole anterior maxillary crown height and a band of contiguous maxillary gingiva (figure 3). The total lip elevation length was defined as (smiling maxillary central incisor display + gum exposure in smile – resting maxillary central incisor display) to quantify the vertical exposure capacity of the lip. This considers complementary to the smiling/resting external upper lip length ratio variable in representing the upper lip’s vertical contraction during smiling. When no resting maxillary central incisor display was recorded, the total lip elevation was not calculated, since negative resting maxillary central incisor display was not measured.

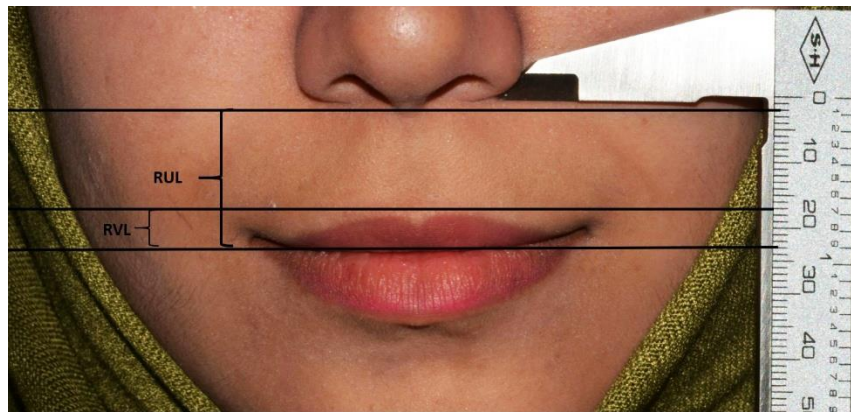


Figure 1. Measurements at rest (RUL, resting upper lip length; RVL, resting vermillion length)

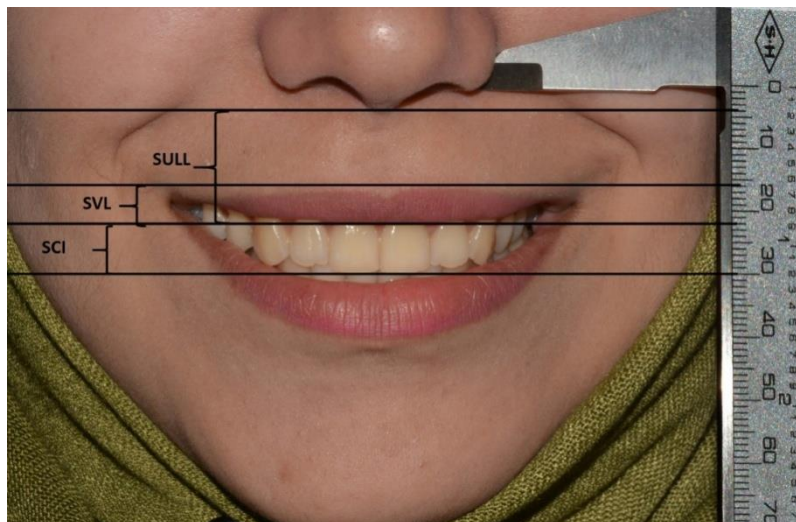


Figure 2. Measurements at smiling (SULL, smiling upper lip length; SVL, smiling vermillion length; SCI, smiling central incisal display)

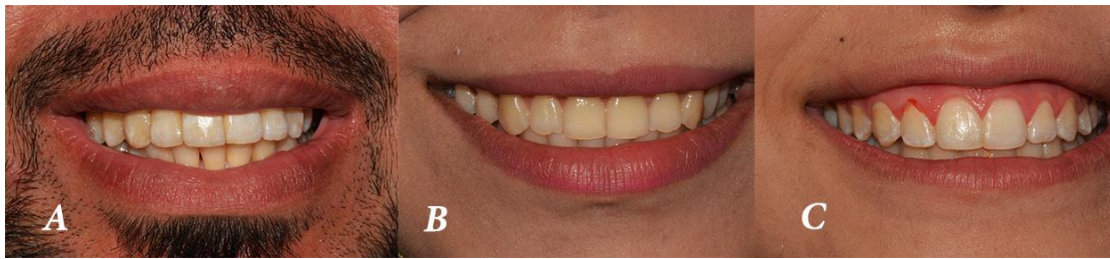

Figure 3. Smile types (A, low smile; B, average smile; C, high smile)

Results

High smiles, with exposure of the entire maxillary incisors and a band of gingiva, were noticed in 16% of the study sample. Average smiles, noticed in 37 % of the subjects, were more common in female (38%) than in male (35%). Low smiles were noticed in 47% of the subjects and were more than in women (48%) than men (47%) were. Table I summarizes the smile patterns by genders.

As summarized in table II, some parameters in correlation to the different smile patterns, the external upper lip length with average smile was 1.86 mm greater than the low smile $P = 0.01$. The mean of maxillary central incisor display at rest position in subjects with low smile was 0.22 mm, subjects with average smile was 2.1 mm and subjects with high smile was 9.2 mm $P = 0.00$.

The total lip elevation mean was 4.63 mm in subjects with low smile, subjects with average smile was 8.72 mm and in those with high smile was 0.57 mm ($p = 0.00$).

In the group with low smile, the upper lip length in maximum smiling was 19 % shorter than resting upper lip length. In group with average smile the resting upper lip length was 32% shorter than the resting upper lip length, and in group with high smile the maximum smiling upper lip length was 23% shorter than resting upper lip.

Discussion

Exposure of teeth and soft tissue (gingiva) during smiling are challenging issues to many physicians, especially those who deal with smile esthetics, overexposure of teeth and gingival tissues is considered by many to be unattractive and usually requires intervention.(Garber & Salama, 2000; Ricketts, 1968; Singer, 1974; Jnzen 1977;Mack, 1996; Silberberg *et al.*, 2009;2006; Ezquerra *et al.* 1999; Miron & Allon, 2012; Landsberg, 2006). Data from this study, similar to other our previous study (Issam, 2014), clearly indicate sexual dimorphism in lip and tooth measurements.

In this study,we use digital photography by use DSLR camera and ruler to assess smile type as use the camera more helpful in smiling design(Ackerman and Ackerman, 2002).

Similar to our previous study, the findings suggest that a low smile pattern can be considered afemale norm(48%), since slightly half of the women in this study don't exposed their gingiva while smiling, and a low smile pattern can be considered a male norm(47%). Similar results and female/male ratios were observed by others in slightly younger population groups. (Tjan *et al.*, 1984; Polo, 2008; Peck *et al.*, 1992).

Although other authors have found a 2:1 ratio of gingival exposure betweenfemale and male subjects, we found of 1 women to 1 man in exposure of gingivae when smiling.(Tjan *et al.*, 1984; Polo, 2008; Peck *et al.*, 1992) In our opinion, this might be attributed to the difference between the study groups because of

mean age or ethnic-related features, and the method of assessment as in this study we use digital photograph, also this study based on class I normal occlusion as the subjects with different dental arch classes can effects on the position and relation of the lips in rest and during smile.(Proffit & Fields, 2000).

Our findings in this study state that the subjects with low smile have an upper lip on average 1.86mm shorter than average smile and this reduction come with gradual reduction in maxillary central incisor display from low, average to high smile, this come with agreement of Mironet *al.*,2012).

As other studies state the smile pattern and efficiency of upper lip elevation, our study come in agreement with it, In our study, the upper lip contracted by 23% of its original height at rest in subjects with a high smile pattern, by 32% in the average smile pattern group, and by 19% in the low smile pattern group. According to Peck *et al.*, subjects with a gummy smile pattern (more than 2 mm of gingival exposure in maximum smiling) had 20% more muscular capacity to raise the upper lip than did subjects without a gummy smile.

Conclusions

As the digital camera today available in each clinic so it helps in diagnosis and archiving dentist work also photography can be used to assess smile types. Low smile was prominent among female and male and the variation in smile types may be related partially to the maxillary central incisor display and total lip elevation.

References

- Ackerman JI, Ackerman MB, Brensinger CM, Landis JR (1998) A morphometric analysis of the posed smile. Clin Orth Res 1:2–11.
- Ackerman Marc and Ackerman James. Smile Analysis and Design in the Digital Era. JCO/April 2002.
- Adams GR. Physical attractiveness, personality, and social reactions to peer pressure. J Psychol 1977; 96(2d half):287-96.
- Amasha Hamad F. Dental Crowding in Relation to Maxillary Morphology in Skeletal Class I Iraqi Sample Aged 17-24 Years (Three-Dimensional Study). A master thesis, Department of Orthodontics Dentistry, University of Baghdad, 2002.
- Andries F, Wevers CW, Wintzen AR, Busch HF, Howeler CJ, de Jager AE, et al. Vocational perspectives and neuromuscular disorders. Int J Rehabil Res 1997; 20:255-73.
- Ezquerria F, Berrazueta MJ, Ruiz-Capillas A, Arregui JS. New approach to the gummy smile. Plast Reconstr Surg 1999;104: 1143-50.
- Garber DA, Salama MA. The aesthetic smile: diagnosis and treatment. Periodontol 2000;1996:18-28.
- Issam M. Abdullah. Upper Lip Changes and Gingival Exposure on Smiling In Group with Class I Normal Occlusion. Journal of Babylon University/Pure and Applied Sciences/ No.(7)/ Vol.(22): 2014.
- Janzen EK. A balanced smile—a most important treatment objective. Am J Orthod 1977; 72:359-72?
- Janzen EK. A balanced smile—a most important treatment objective. Am J Orthod 1977;72:359-72.
- Landsberg CJ, Sarne O. Management of excessive gingival display following adult orthodontic treatment: a case report. Pract Proced Aesthet Dent 2006;18:89-94.
- Mack MR. Perspective of facial esthetics in dental treatment planning. J Prosthet Dent 1996;75:169-76.

- Mackley, R.J.: "Animated" orthodontic treatment planning, *J. Clin. Orthod.* 27:361-365, 1993.
- Miron, Calderon, and Allon. Upper lip changes and gingival exposure on smiling: Vertical dimension analysis. *Am J Orthod Dentofacial Orthop* 2012;141:87-93.
- Morley, J. and Eubank, J.: Macroesthetic elements of smile design, *J. Am. Dent. Assoc.* 132:39-45, 2001.
- Obaidi Hussain A. and Manar Y Abdul-Qadir. Evaluation of the variation of skeletofacial angles (facial, mandibular, and gonial angles) among the pubertal age groups: (A cephalometric study). *J Bagh Coll Dentistry* 2007; 19(1):101-106.
- Peck S, Peck L, Kataja M. Some vertical lineaments of lip position. *Am J Orthod Dentofacial Orthop* 1992;101:519-24.
- Peck S, Peck L, Kataja M. The gingival smile line. *Angle Orthod* 1992;62:91-100.
- Peck, S.; Peck, L.; and Kataja, M.: The gingival smile line, *Angle Orthod.* 62:91-100, 1992.
- Polo M. Botulinum toxin type A (Botox) for the neuromuscular correction of excessive gingival display on smiling (gummy smile). *Am J Orthod Dentofacial Orthop* 2008;133:195-203.
- Proffit WR and Fields HW. *Contemporary Orthodontics*. Chicago: Mosby 2000.
- Ricketts RM. Esthetics, environment, and the law of lip relation. *Am J Orthod* 1968;54:272-89.
- Scavone Jr, Zahn-Silva, Do Valle-Corotti, Naha S. Soft Tissue Profile in White Brazilian Adults with Normal Occlusions and Well-Balanced Faces. *Angle Orthodontist* 2008;78(1):58-63.
- Silberberg N, Goldstein M, Smidt A. Excessive gingival display—etiology, diagnosis, and treatment modalities. *Quintessence Int* 2009;40:809-18.
- Singer RE. A study of the morphologic, treatment, and esthetic aspects of gingival display. *Am J Orthod* 1974;65:435-6.
- Sneddon J. Myasthenia gravis: a study of social, medical, and emotional problems in 26 patients. *Lancet* 1980;1(8167):526-8.
- Stevenage SV, McKay Y. Model applicants: the effect of facial appearance on recruitment decisions. *Br J Psychol* 1999; 90:221-34.
- Tjan AH, Miller GD, The JG. Some esthetic factors in a smile. *J Prosthet Dent* 1984;51:24-8.
- Uysal, Usumez, Memili, Sari. Dental and Alveolar Arch Widths in Normal Occlusion and Class III Malocclusion. *Angle Orthod* 2005;75:809–813.
- Vitral Robert Willer Farinazzo, Marcio Jose da Silva Campos, Andreia Fialho Rodrigues, and Marcelo Reis Fraga. Temporomandibular joint and normal occlusion: Is there anything singular about it? A computed tomographic evaluation. *Am J Orthod Dentofacial Orthop* 2011;140:18-24.

Table I. Smile pattern by sex

<i>mile type</i>	Female	male	total
Low smile	10 (48%)	8 (47 %)	18 (47%)
Average smile	8 (38%)	6 (35 %)	14 (37 %)
High smile	3 (14%)	3(18%)	6 (16%)
total	21 (100%)	17 (100%)	38 (100%)

Table II. Lip measurements by smile pattern

factors	Low smile		Average smile		High smile		1-way ANOVA	Low - average	Average-high	High -low
	mean	SD	mean	SD	mean	SD		t-test	t-test	t-test
Resting external upper lip length (mm)	18.91	1.62	20.77	2.42	19.93	1.60	0.04	0.01	0.39	0.27
Resting maxillary central incisor display length (mm)	0.22	0.65	2.10	1.92	9.2	0.15	0.00	0.00	0.00	0.00
Total lip elevation (mm)	4.63	1.34	8.72	1.31	0.57	0.36	0.00	0.00	0.00	0.00
Smiling/resting external upper lip length ratio	0.81	0.12	0.68	0.07	0.77	0.03	0.00	0.00	0.06	0.38